


Pathologist Directed US Biopsy



JOHN S. ABELE, MD
OUTPATIENT PATHOLOGY ASSOCIATES

3301 C Street; Suite 103C
 Sacramento, CA 95816

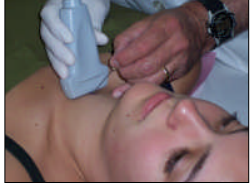
916-444-0889 voice
 916-444-6016 fax
 abele@outpatientpathology.com
 Moira Kelly, Service Representative

OPA / UCSF

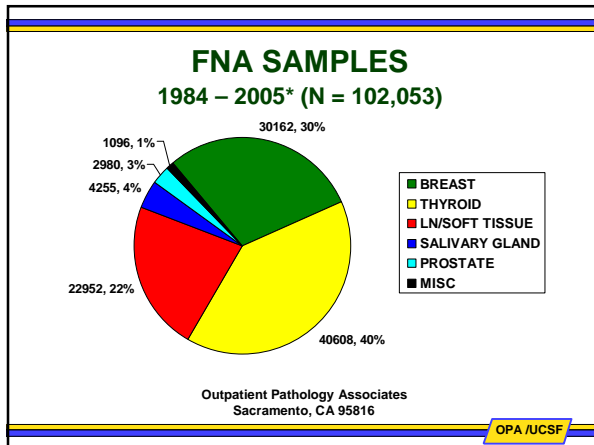
Pathologist US Guided FNA & Core Bx

** US = 3D Palpation = GPS for FNA **

- Illustrative Cases
- Equipment
- Basic Technique
- Billing & Reimbursement
- Learning Models & References



OPA / UCSF



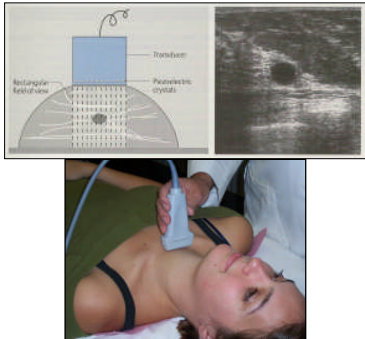
FINE NEEDLE ASPIRATION CASES

SITE	2005	%	1984-2005*	%
BREAST	725	14	30162	30
THYROID	3272	63	40608	40
SOFT/LN	901	17	22952	22
SALIVARY	141	3	4255	4
PROSTATE	0	0	2980	3
MISC	130	3	1096	1
	5,169		102,053	

Outpatient Pathology Associates
 Sacramento, CA 95816

OPA / UCSF

U/S = Palpation in 3rd Dimension



OPA / UCSF

Pathologist US Guided Benefits

- Deep Palpation & Bx
 - Posterior Thyroid
- Edges
 - Carotid / Trachea
- False Physical Image
- Patient Communication
- Better Sample Than Radiologist
- Market Forces - TTHALTS

OPA / UCSF

Pathologist Directed US Biopsy

Case 1

- 59 y/o male
- 4 x 2 cm distal thigh mass
- Hard, enlarging

OPA / UCSF

59 y/o 3CM Thigh Mass

Benign Features:
Wider than Tall
Smooth, Pushing Borders

OPA / UCSF

59 y/o 3CM Thigh Mass

OPA / UCSF

Case 2

- 81 y/o female
- L Br 2:30, 31 x 26mm
- Targeting US = WNL
- Just lateral -> 9mm shadow

OPA / UCSF

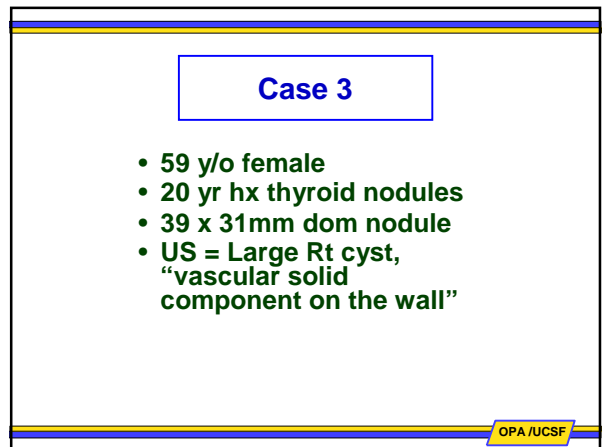
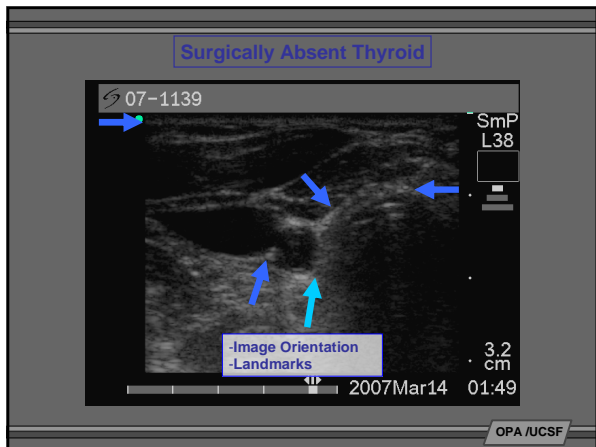
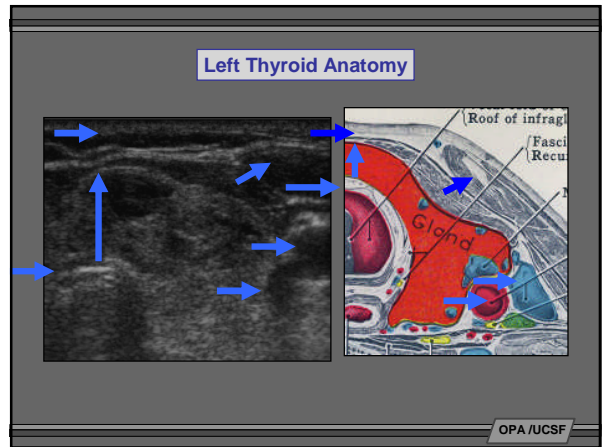
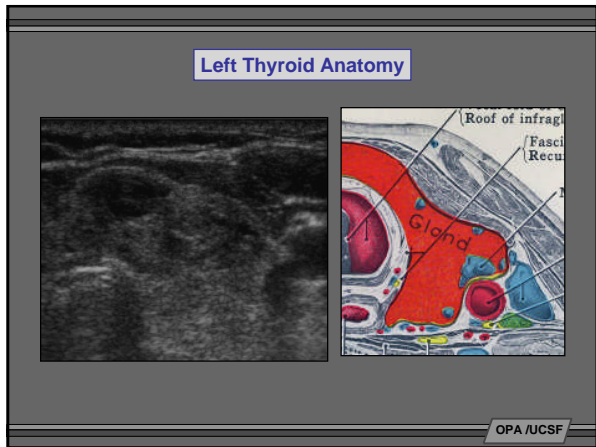
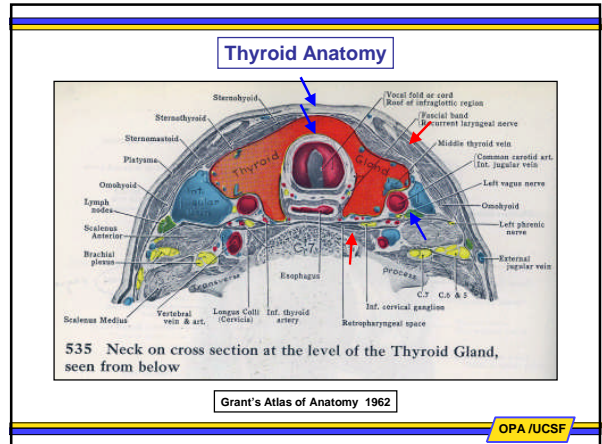
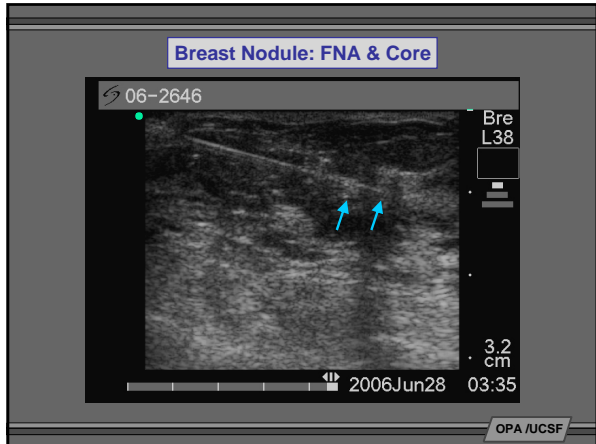
Breast Nodule: FNA & Core

OPA / UCSF

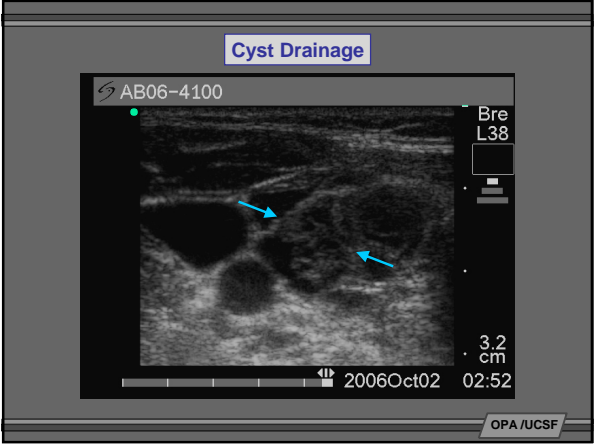

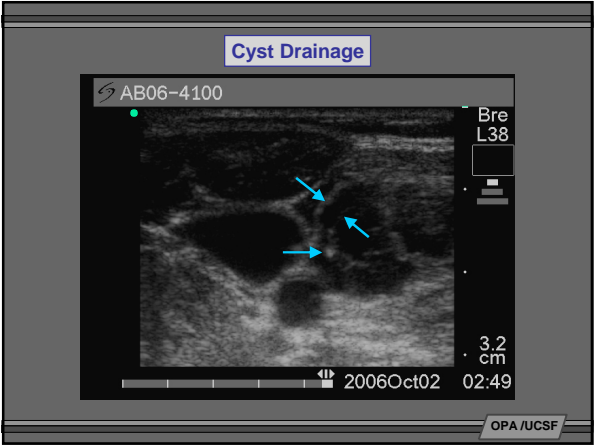
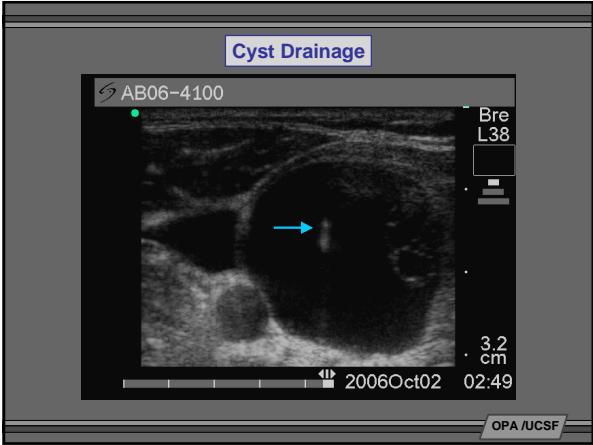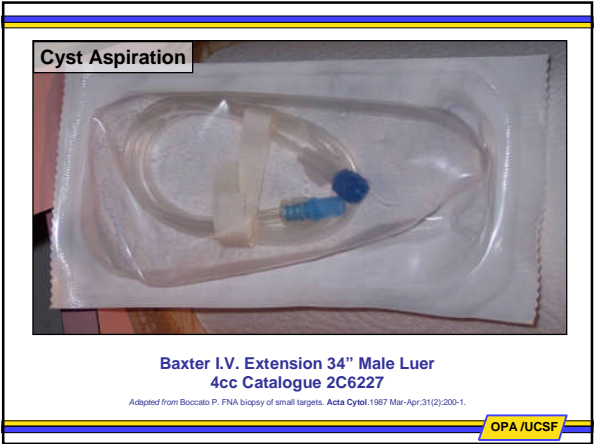
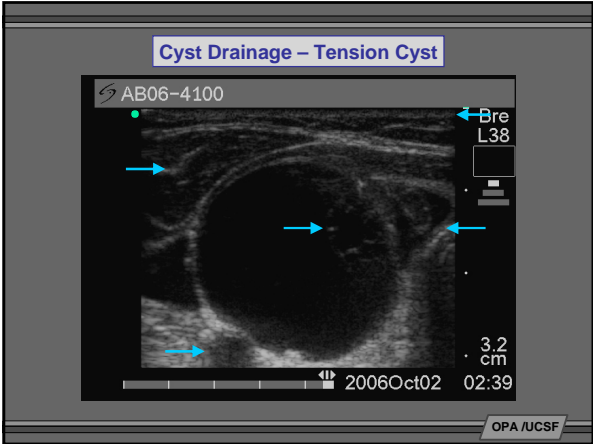
Breast Nodule: FNA & Core

OPA / UCSF

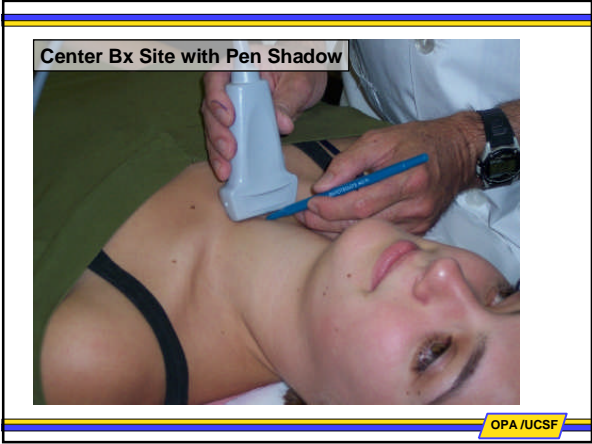
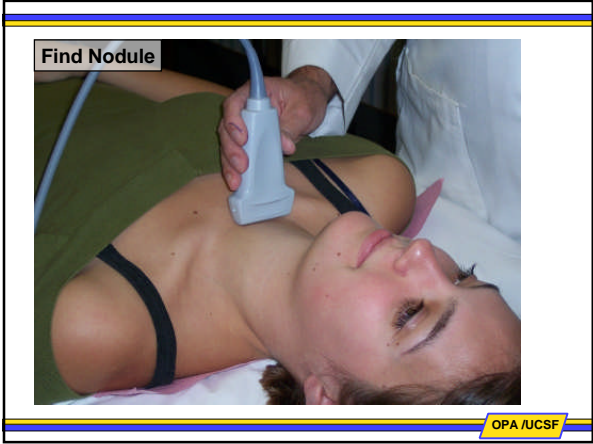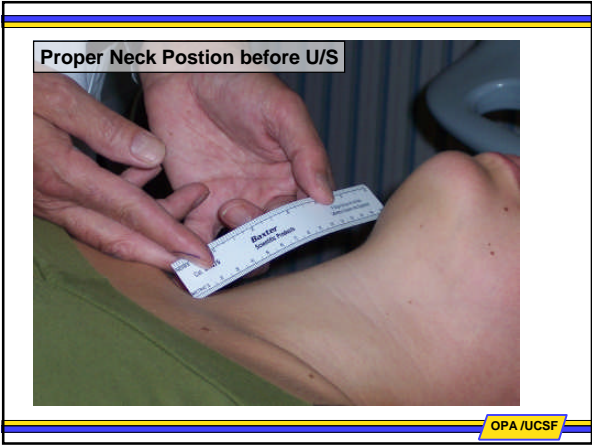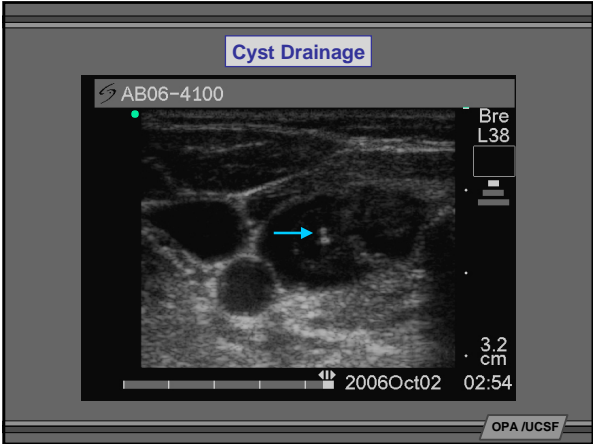
Pathologist Directed US Biopsy



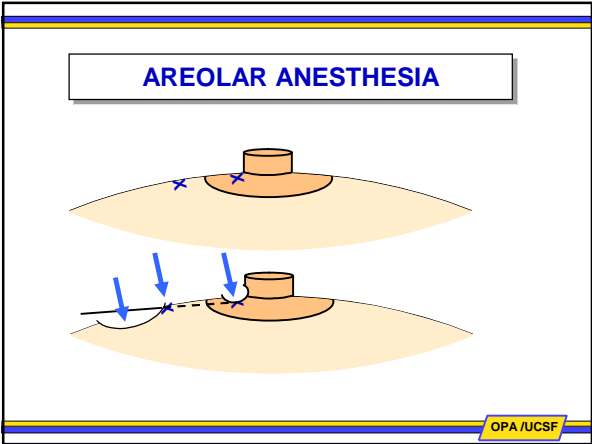
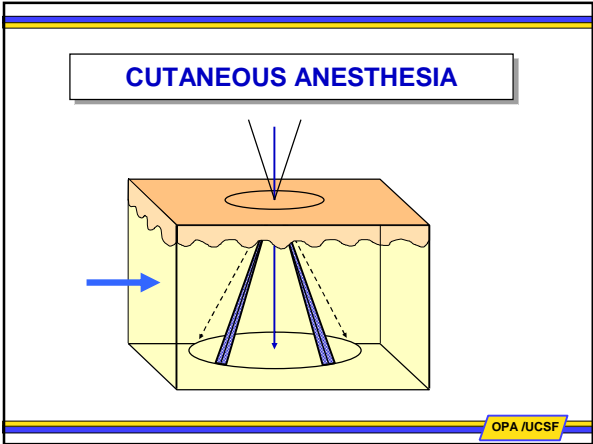
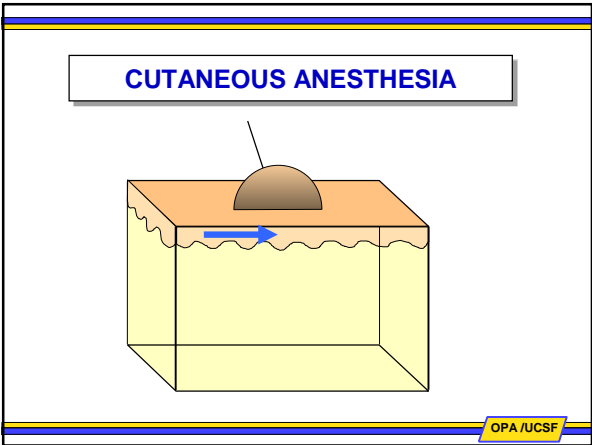
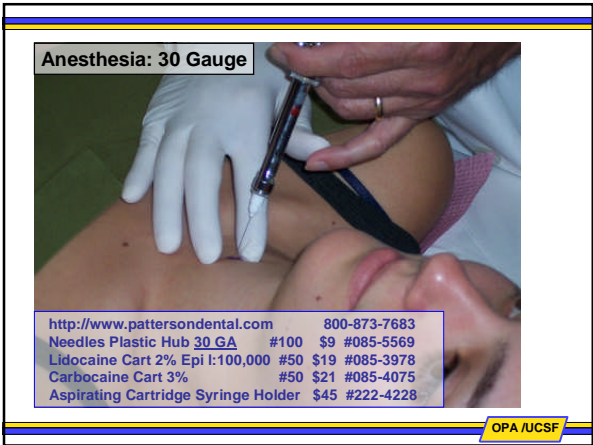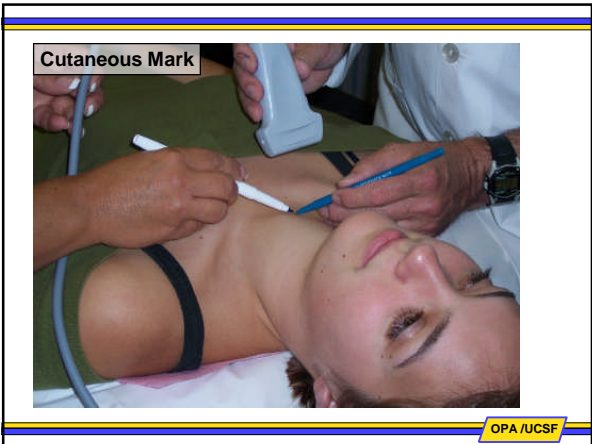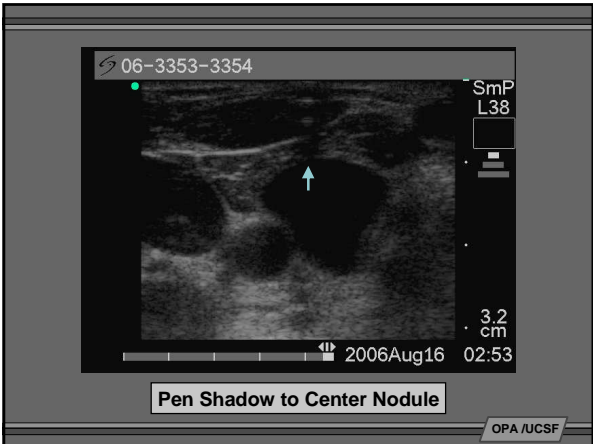
Pathologist Directed US Biopsy




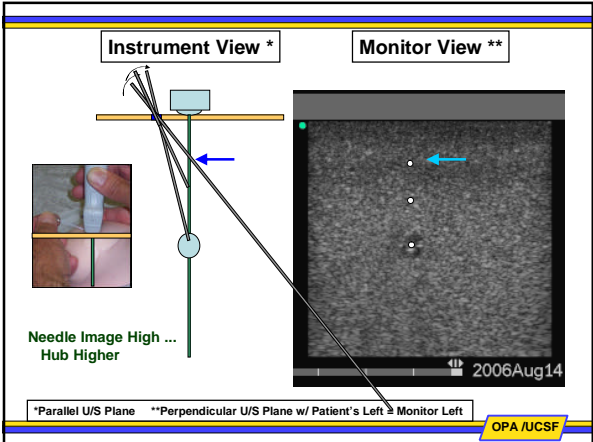
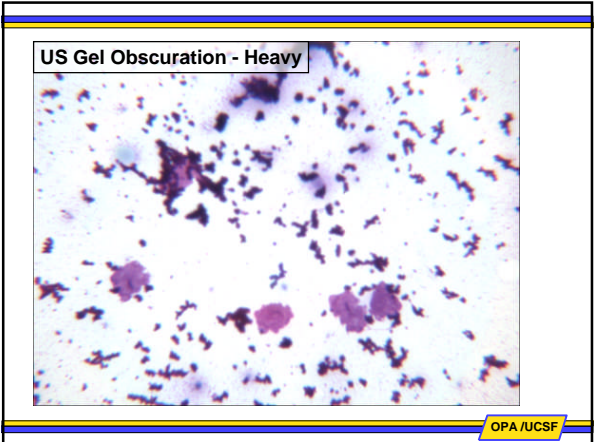
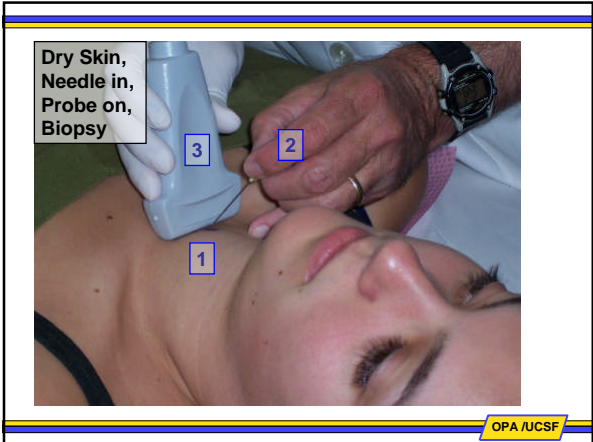
Pathologist Directed US Biopsy



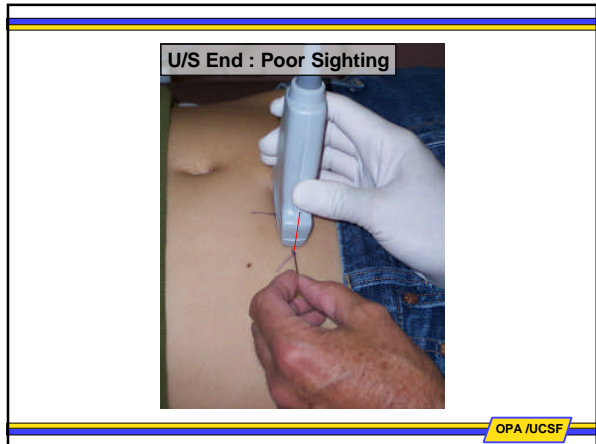
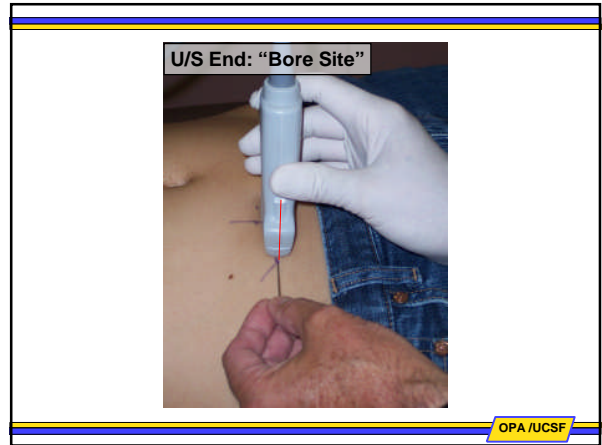
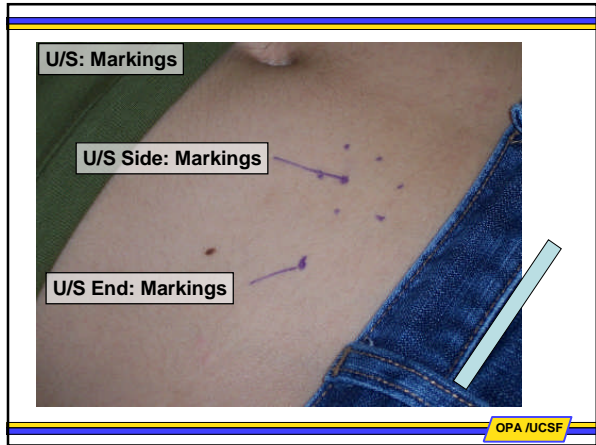
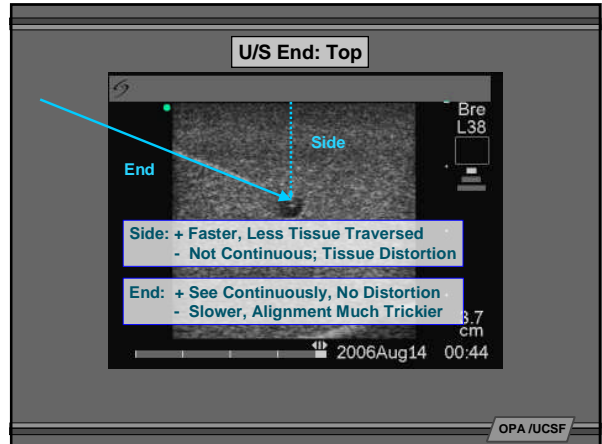
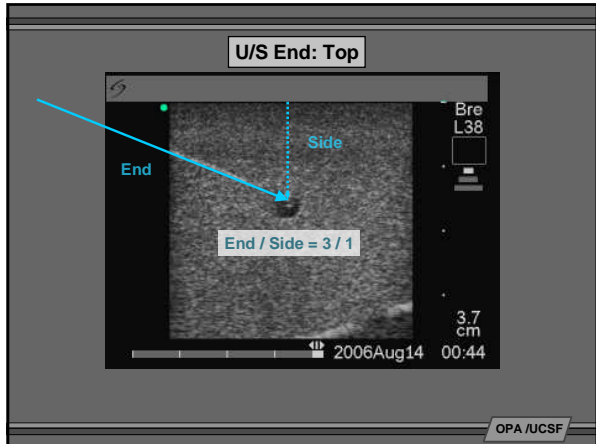
Pathologist Directed US Biopsy



Pathologist Directed US Biopsy



Pathologist Directed US Biopsy

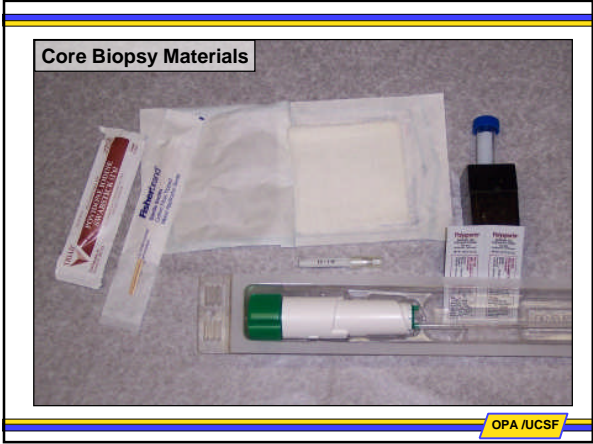
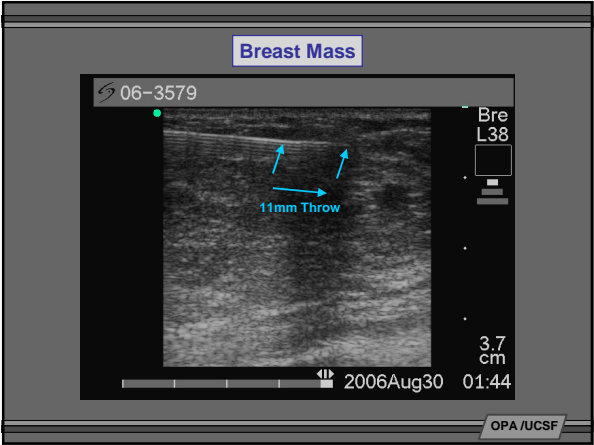
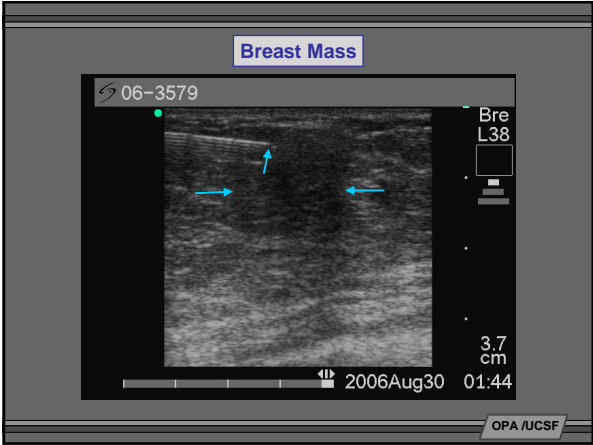
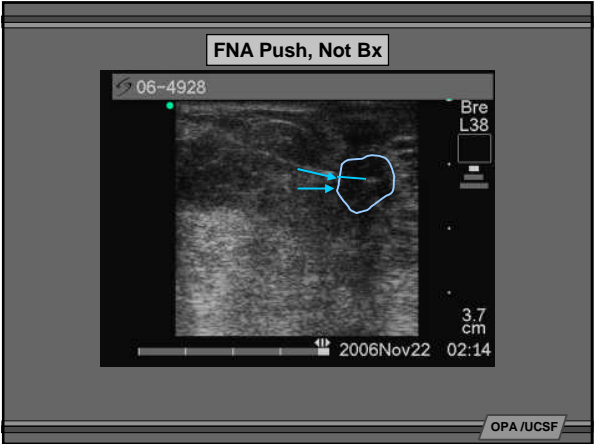
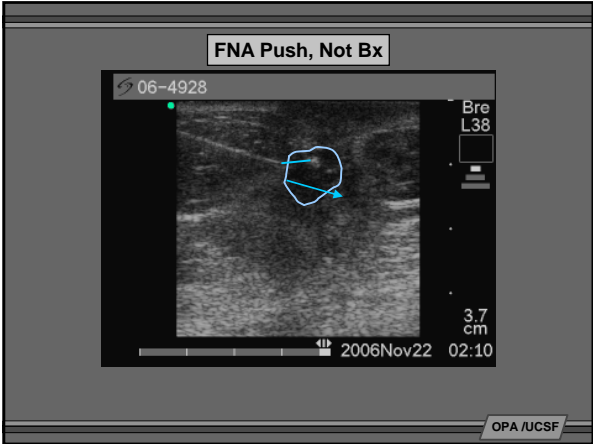


How Core Benefits Br FNA

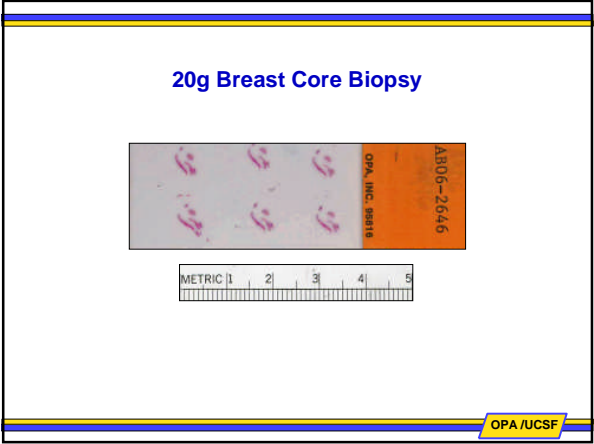





- **Prove Invasion**
- **Material for Special Studies**
- **Mobile / Soft Target**
 - FAD / Low Tension Cyst
- **FAD vs. Circumscribed CA**
 - Colloid / Medullary / Met CA
- **Backup to FNA**

OPA / UCSF

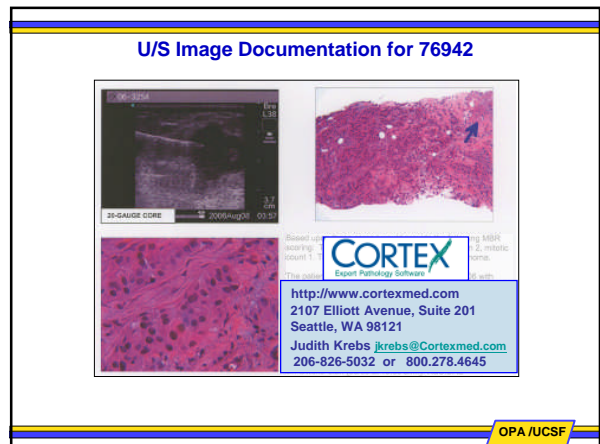
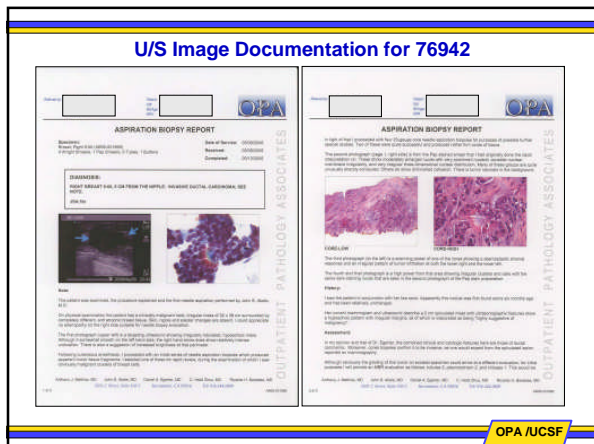
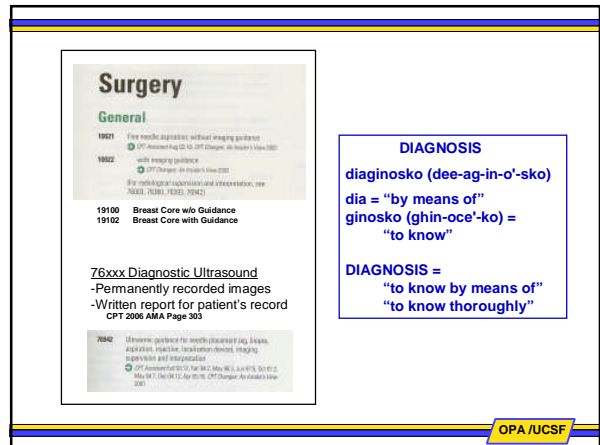
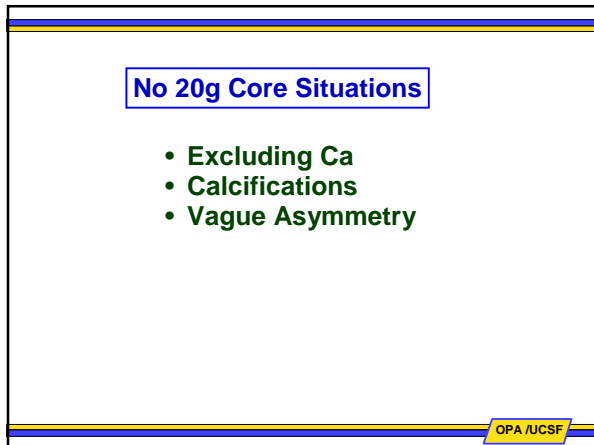
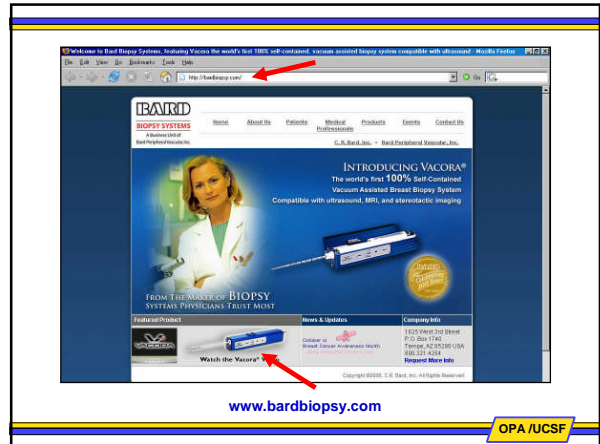
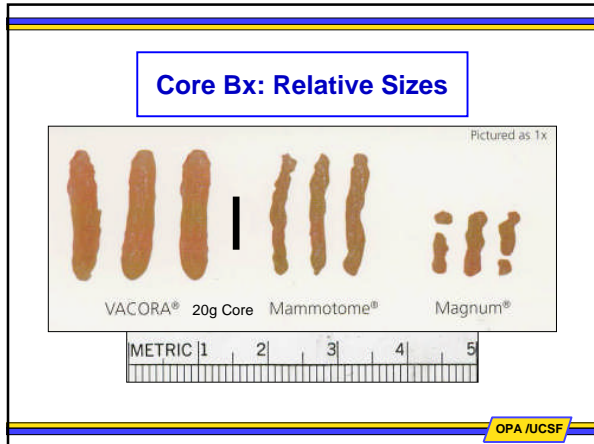
Pathologist Directed US Biopsy



Pathologist Directed US Biopsy



Pathologist Directed US Biopsy



Pathologist Directed US Biopsy

Billing/Paid Jan-June 2006					
Item	CPT	#	Billed	Paid	Range
FNA Bx	10021	434	151.00	108.69	144 - 63
US FNA Bx	10022	278	175.00	121.99	160 - 57
US ImglRpt	76942*	327	150.00	116.74	150 - 72
FNA DX	88173	1988	169.00	118.33	155 - 56
Rapid	88172	29	175.00	53.72	56 - 45
Head/Neck	76536*	123	150.00	95.99	135 - 70
Breast	76645*	29	150.00	72.27	86 - 49
Extremity	76880*	15	150.00	110.76	125 - 89

* Requires Permanent Image & Written Report

OPA / UCSF

Billing/Paid Jan-June 2006					
Item	CPT	#	Billed	Paid	Range
Core	19100	1	200.00	136.00	
Core\US	19102	9	275.00	241.19	
US ImglRpt	76942	327	150.00	116.74	150 - 72
Section	88305	5567	188.00	132.26	
Office 30**	99242	336	94.00	80.00	94 - 75
No FNA	99242	336	94.00	80.00	94 - 75
Office 15*	99241	420	64.00	51.78	64 - 41

** 2 sites, complex, translator
* 1 site

OPA / UCSF

Editorials

Radiology

Mary C. Frates, MD
Carol B. Benson, MD
J. William Charboneau, MD
Edmund S. Cibas, MD
Otto H. Clark, MD
Beverly G. Coleman, MD
John J. Croshaw, MD
Peter M. Doubilet, MD, PhD
Douglas R. Evans, MD
John R. Goellner, MD
Ian D. Hay, MD, PhD
Barbara S. Hertzberg, MD
Charles M. Intenzo, MD
R. Brooke Jeffrey, MD
Jill E. Langer, MD
P. Reed Larsen, MD
Susan J. Mandel, MD
William D. Middleton, MD
Carl C. Reading, MD

Management of Thyroid Nodules Detected at US: Society of Radiologists in Ultrasound Consensus Conference Statement¹

The Society of Radiologists in Ultrasound convened a panel of specialists from a variety of medical disciplines to come to a consensus on the management of thyroid nodules identified with thyroid ultrasonography (US), with particular focus on which nodules should be subjected to US-guided fine needle aspiration and which thyroid nodules need not be subjected to fine-needle aspiration. The panel met in Washington, DC, October 26-27, 2004, and created this consensus statement. The recommendations in this consensus statement, which are based on analysis of the current literature and common practice strategies, are thought to represent a reasonable approach to thyroid nodular disease.
© ISU, 2005

Radiology 2005; 237:794-800

Brant WE. The core curriculum: Ultrasound. 2001 Thy = 10 of 509.

OPA / UCSF

Figure 1. Punctate echogenicities in thyroid nodules. (a) Sagittal US image of nodule (arrowheads) containing multiple fine echogenicities (arrow) with no comet-tail artifact. These are highly suggestive of malignancy. FNA and surgery confirmed papillary carcinoma. (b) Transverse US image of nodule (arrowheads) containing cystic areas with punctate echogenicities and comet-tail artifact (arrow) consistent with colloid crystals in a benign nodule.

Radiology 2005; 237:794-800

OPA / UCSF

TABLE 2
Recommendations for Thyroid Nodules 1 cm or Larger in Maximum Diameter

US Feature	Recommendation
Solitary nodule	
Microcalcifications	Strongly consider US-guided FNA if ≥ 1 cm
Solid (or almost entirely solid) or coarse calcifications	Strongly consider US-guided FNA if ≥ 1.5 cm
Mixed solid and cystic or almost entirely cystic with solid mural component	Consider US-guided FNA if ≥ 2 cm
None of the above but substantial growth since prior US examination	Consider US-guided FNA
Almost entirely cystic and none of the above and no substantial growth (or no prior US)	US-guided FNA probably unnecessary
Multiple nodules	Consider US-guided FNA of one or more nodules, with selection prioritized on basis of criteria (in order listed) for solitary nodule*

Note.—FNA is likely unnecessary in diffusely enlarged gland with multiple nodules of similar US appearance without intervening parenchyma. Presence of abnormal lymph nodes overrides US features of thyroid nodule(s) and should prompt US-guided FNA or biopsy of lymph node and/or ipsilateral nodule.
* Panel had two opinions regarding selection of nodules for FNA. The majority opinion is stated here.

Radiology 2005; 237:794-800

OPA / UCSF

THYROIDOLOGISTS
Experts in the Diagnosis and Treatment of Thyroid Disease

Table 1

Indications for UG FNA of Thyroid Micronodules (0.5-1cm)

- History of radiation to head or neck during childhood
- Family history of medullary or papillary thyroid cancer
- Micronodule in remaining lobe after hemithyroidectomy for thyroid cancer
- Hyperechoic micronodule with one or more of the following ultrasound findings:
 - Blurred margins
 - Intramodular vascularity
 - Taller than wide
 - Microcalcifications
 - Significant neck lymphadenopathy

Academy of Clinical Thyroidologist
(www.thyroidologists.com)

OPA / UCSF

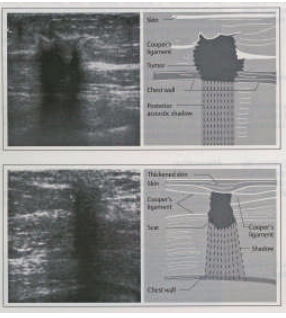
Pathologist Directed US Biopsy

The Practice of Breast Ultrasound
Techniques · Findings
Differential Diagnosis

Helmut Madjar, M.D.
German Clinic for Diagnosis
Wiesbaden, Germany

With the collaboration of
Jack Jellins, PhD, FAIUM, FACPSEM
President of the International
Breast Ultrasound School
Sydney, Australia

With 366 illustrations in
731 separate panels and 73 tables



OPA / UCSF

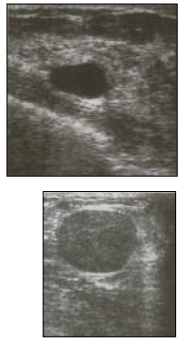


Fig. 4.5 Typical cyst:

Shape	Oval
Contours	Smooth
Margins	Sharp
Internal structure	Homogeneous
Echogenicity	Anechoic
Sound transmission	Enhanced
Edge shadows	Fair lateral shadows
Size	7 x 10 mm
Axial orientation	Horizontal
Compressibility	Slight
Mobility	Moderate

Comment: Typical cysts can be confidently diagnosed with ultrasound. Atypical cysts lead to problems of differential diagnosis (Chap. 6).

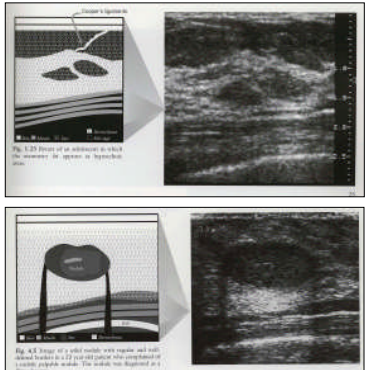
OPA / UCSF

**BREAST
ULTRASOUND**

Dr. M. E. Lanfranchi, M.D.
Professor of Ultrasound
The Argentine Society of Ultrasound in Medicine and Biology,
The Latin American Federation of Societies of Ultrasound in Medicine and Biology,
Chief, Section of Ultrasonography, Dr. A. Debas Hospital

OPA / UCSF

**Lanfranchi
Breast Ultrasound**



OPA / UCSF